Using a Thermal Imaging Camera to Detect Temperature Differences Between Normal Stifles and Stifles with Cranial Cruciate Ligament Ruptures in Dogs

Abstract:

Cranial cruciate ligament ruptures have traditionally been diagnosed with the use of MRI, radiographs, and physical exam findings. Thermal imaging has been used in medicine to diagnose joint inflammation and rheumatoid arthritis in children, foot dermatitis in cattle, and lameness in horses. There are no studies that have been conducted to assess the ability of a thermal imaging camera to diagnose cranial cruciate ligament ruptures in dogs. A thermal imaging camera was used to assess the temperature from four different views in a stifle with a cranial cruciate ligament rupture and the opposite healthy stifle in the same dog. Data from fifty patients was collected at the Red Bank Veterinary Hospital with the FLIR thermal imaging camera. An unpaired student's t-test was used to determine statistical significance between groups. There were no statistically significant differences between affected and unaffected stifles, thus proving the null hypothesis.

Introduction:

Veterinary medicine poses unique challenges in the diagnosis of orthopedic diseases in many types of animals. Although multiple orthopedic injuries are able to be observed through technologies such as MRI and radiographs, other diagnoses pose difficulties due to characteristics of the animals and the environments in which observation takes place. It would be

useful to have a technology which could identify an injured joint from a distance eliminating the need to physically restrain an uncooperative animal. Traditional methods of diagnosis are not applicable in many settings of the veterinary world, ranging from horses on a range to lions in the Serengeti. Thermal imaging has gained popularity throughout the medical community for the relatively simple and convenient diagnosis that the technology provides. Although thermal imaging has been tested in the diagnosis of children, cattle, and horses, studies on cranial cruciate ligament ruptures in dogs with this technology have never been performed. In this study, a large group of dogs were examined to determine if this technology had the ability to predict which stifle was affected in a given patient. The research hypothesis is that thermal imaging of a dog's stifle in various angles will be able to detect a temperature difference between the uninjured side and the side with a cranial cruciate ligament rupture. The null hypothesis is that thermal imaging of a dog's stifle in various angles will not be able to detect a temperature difference between the uninjured side and the side with a cranial cruciate ligament rupture.

Materials and methods:

Dogs that presented to the Red Bank Veterinary Hospital over an eight-month period were eligible for inclusion in the study. Each dog had to have a confirmed cranial cruciate ligament rupture in one stifle with a completely normal opposite stifle (no palpable effusion, pain, or previous surgical procedures). The subjects also had no dermatologic abnormalities. Each dog had the lateral, medial, cranial, and caudal views of both stifles taken with a T-620 FLIR thermal imaging camera from a distance of 12-24 inches from the stifle. Using FLIR imaging software, the outline of the stifle joint was identified and the maximum temperature was recorded within this outline. (See figure 1) Each dog had data recorded which included age, sex,

neuter status, temperature, presence of a meniscal tear, complete versus partial ligament rupture, degree of lameness, degree of osteoarthritis, duration of injury, current medications, body condition score, long versus short hair, maximal thigh circumference, and any concurrent disease. The maximum temperatures for each view of the affected (torn cranial cruciate ligament) were compared to the maximal temperature of the unaffected (normal) stifle with an unpaired student's t-test with significance determined to be at a p value of <0.05. The difference between the average affected and normal stifle in degrees Fahrenheit was recorded. This value was used to determine if any recorded characteristic was associated with a more likely positive (affected stifle warmer than the unaffected stifle) test result with an unpaired student's t-test.

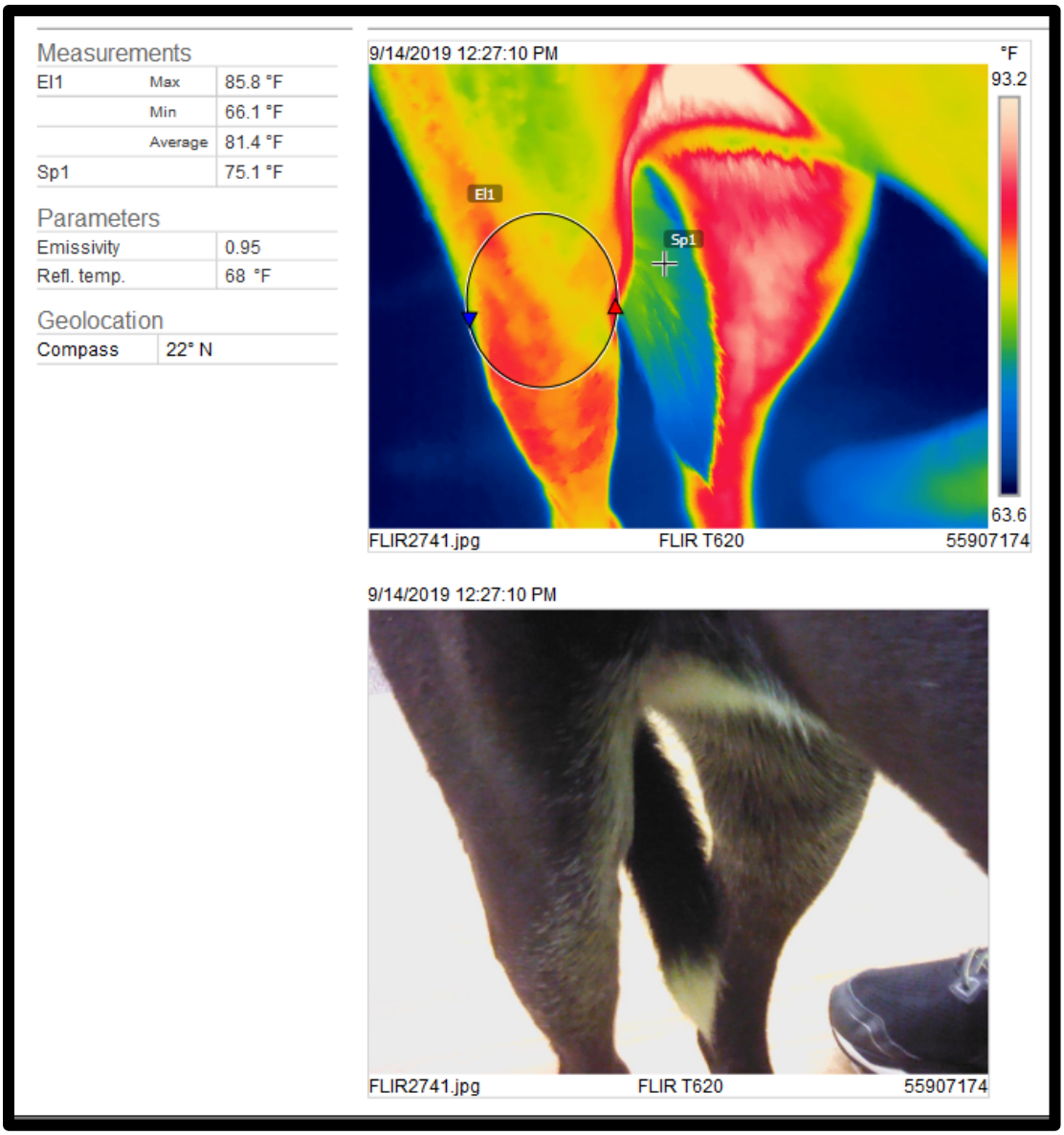

Figure 1: Cranial view of a dog's stifle using the FLIR thermal imaging camera with thermal and traditional pictures as well as recorded maximal temperature within the outline of the stifle joint.

Results:

Fifty dogs were examined at Red Bank Veterinary Hospital over an 8th month study period which met the criteria for inclusion. Pictures were taken of each of these dogs with owner's consent. The medical records of each of these dogs were used to record the

characteristics of each of the dogs. All of the maximal temperatures within the outline of the stifle were recorded. (see figure 2) There was no significant difference found between the affected and the unaffected stifles in any of the views recorded.

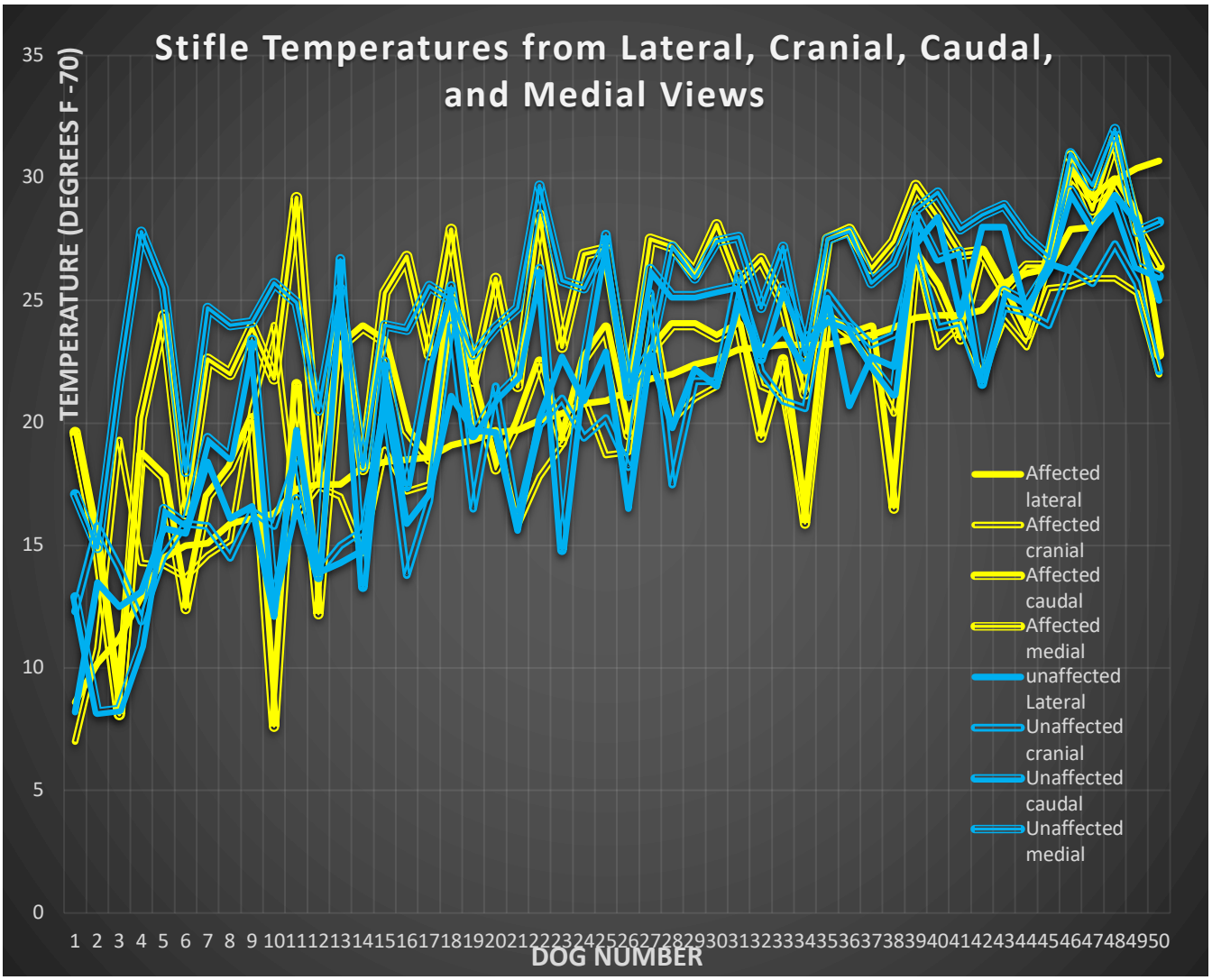

Figure 2: Line chart of each of the temperatures recorded from lateral, cranial, caudal and medial views. Each of the yellow lines indicate a temperature from the injured stifle and each of the blue lines indicate temperatures from the normal stifle. (A significant difference would be demonstrated if all of the yellow lines were higher than each of the blue lines)

The average stifle temperatures were recorded (sum of all four views/4). (see table 1). There was no significant difference seen between the injured or normal stifles.

Table 1: Average stifle temperatures from all 4 views in 50 dogs between injured and normal stifles.

All temperatures in the study were measured in degrees Fahrenheit	**Affected Stifle Average Maximum Temperature**	**Unaffected Stifle Average Maximum Temperature**	**P-Value** (Student's Unpaired T-Test)
Lateral view	90.79	90.62	0.86
Cranial view	90.04	90.12	0.93
Caudal view	91.42	91.74	0.74
Medial view	94.61	95.40	0.35

Each of the average temperatures was used and the difference between the affected and normal stifles was recorded. A positive test was determined to be a higher temperature of the affected than the normal stifle. When looking at each of the characteristic of the dogs in the study, there was no significance difference seen between all groups except when comparing dogs on non-steroidal anti-inflammatory drugs (NSAIDs) to dogs who were not on NSAIDs. (see figure 3 and table 2)

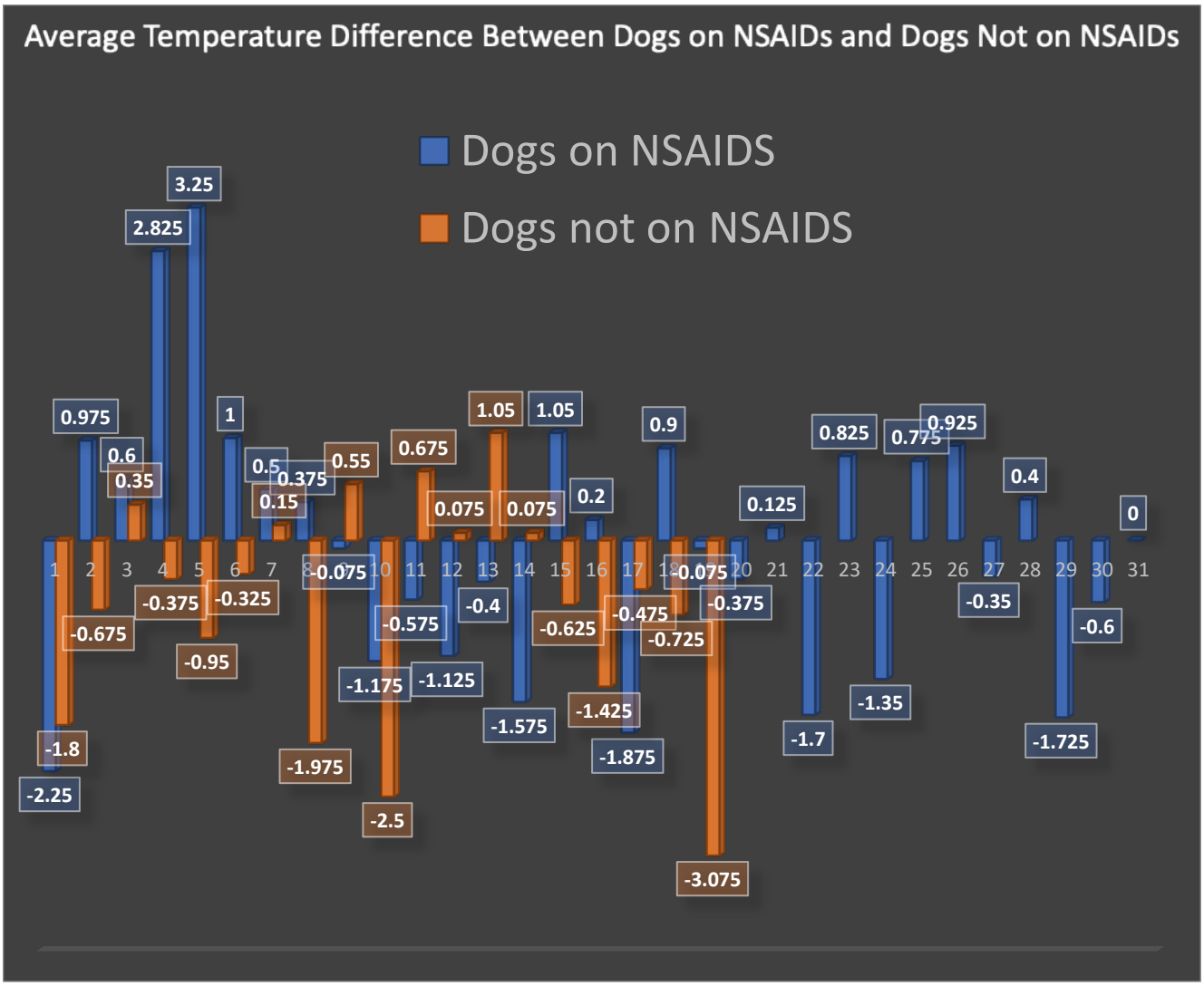

Figure 3: Bar graph demonstrating significant difference in the affected vs normal stifles in dogs not on NSAIDs. Notice that in the orange bars (dogs not on NSAIDS), a greater proportion of dogs have a positive test (values area negative and thus the injured stifle has a greater temperature than the normal stifle) than the blue bars (dogs on NSAIDs).

Table 2: Characteristics of dogs as related to the ability of the FLIR camera to determine which stifle is injured vs normal

Characteristic Measured All data was measured for a significant difference between the groups using the average temperature variation between affected and unaffected stifles.	**P-Value (Student's Unpaired T-Test)** (Significant values $p<0.05$)
Age (dogs under 5 years old versus dogs 5 years old or older)	0.67
Gender (males versus females)	0.91
Neuter (spayed/castrated versus intact)	0.61
Hair Length (long hair versus short hair)	0.40
Duration (limping for less than 30 days versus limping for 30 days or more)	0.70
Severity of Tear (complete cruciate tear versus partial cruciate tear)	0.68
Weight (dogs under 30 kilograms versus dogs 30 kilograms or over)	0.32
Meniscus (torn versus healthy)	0.21
Body Temperature (lower than 101.5 degrees Fahrenheit versus 101.5 degrees Fahrenheit or above)	0.36
Body Condition Score (normal weight versus overweight)	0.88
Degree of Lameness (mild/moderate versus severe)	0.86
Osteoarthritis (minimal versus moderate/severe)	0.92
Anti-Inflammatories (dogs on anti-inflammatories versus dogs not on anti-inflammatories)	0.03

Conslusions:

In this study, it was show that a thermal imaging camera can be used to detect a dog's stifle temperature from multiple views. The camera was easy to use and gave a repeatable measurement of the temperature of a dog's stifle. It was shown that there is no statistically significant evidence that this technology can differentiate between injured and uninjured stifles in this cohort of dogs. It was also shown that there was a more reliable temperature difference between affected and unaffected stifles in dogs when the subjects were not on anti-inflammatories. This may be due to the fact that anti-inflammatory medications have the ability to lower the temperature of an injured inflamed stifle and thus make a temperature difference harder to detect when these medications are used. The majority of dogs in this study were on anti-inflammatory medications and this may have affected the results.

This data strongly supports the null hypothesis. Based on this study, the use of a FLIR thermal imaging camera should not be relied upon to make the diagnosis of a cranial cruciate ligament rupture in dogs. Future studies could include the measurement of carpal or tarsal injuries since these joints are closer to the surface of the skin and could possibly improve thermal imaging accuracy. A larger group of stifle joints in dogs that are not being treated with anti-inflammatories may improve the ability of this technology to detect injuries. Also, studies on the ability of a thermal imaging camera to assess cranial cruciate ligament ruptures in humans could further the research to see if this technology is more accurate in species without fur.

Bibliography:

Westerman, S. et. all (2013). Effects of infrared camera angle and distance on measurement and reproducibility of thermographically determined temperatures of the distolateral aspects of the forelimbs in horses. Retrieved September 10, 2019 from https://avmajournals.avma.org /doi/abs /10.2460/javma.242.3.388

Seuser, A., & Karin Kurnik, A.-K. M. (2018). [PDF] Infrared Thermography as a Non-Invasive Tool to Explore Differences in the Musculoskeletal System of Children with Hemophilia Compared to an Age-Matched Healthy Group - Semantic Scholar. Retrieved September 6, 2019 from https://www.semanticscholar.org/paper/Infrared-Thermography-as- a-Non-Invasive-Tool-to-in-Seuser-Kurnik/fa7d98dec417a55506fa56c1ced5a1c044d28487

Pavelski, Basten, Silva, M. da, Eduarda, Dornbusch, & Triches, P. (2015). Infrared thermography
evaluation from the back region of healthy horses in controlled temperature room. Retrieved September 14 2019 from http://www.scielo.br/scielo.php?script.pt=sciarttext& pid=S 0103-84782015000701274

Sanchis-Sánchez, Enrique et. all (2014). Infrared Thermal Imaging in the Diagnosis of Musculoskeletal Injuries: A Systematic Review and Meta-Analysis : American Journal of Roentgenology : Vol. 203, No. 4 (AJR). (n.d.). Retrieved September 15 2019 from https://www.ajronline.org/doi/10.2214/AJR.13.11716